

7.2.3. Robot-assisted intracorporeal neobladder: Standardized technique

Giovannalberto Pini, Abolfazl Hosseini, Justin Collins, Nils Peter Wiklund

Introduction

Radical cystectomy with extended pelvic lymphadenectomy (ePLND) and urinary diversion still represents the gold standard treatment for muscle invasive bladder cancer and high-risk bladder cancer unresponsive to intravesical treatments. Irrespective of surgical approach RC remains a complex multi-step surgery, being associated with a high rate of complications.^{1,2} With the purpose of further reducing morbidity, minimally invasive approaches have been described and the 2015 EAU-guidelines³ consider laparoscopic radical cystectomy with extracorporeal urinary diversion a viable option. However, laparoscopic radical cystectomy has never gained wide acceptance in the urological community due to long operative time and the technical difficulties related to both ePLND and urinary diversions reconfiguration. With the introduction of robot-assisted laparoscopic surgery, robot-assisted radical cystectomy (RARC) has emerged as a more viable alternative to both the open and laparoscopic approaches to radical cystectomy.⁴

To date, the RARC experience is increasing worldwide, minimizing surgical insult, and aiming to result in reductions in postoperative morbidity while offering improved ergonomics for the surgeon.⁵ Several meta-analyses have demonstrated that RARC decreases blood loss and reduces overall complication rates, resulting in reduced transfusion rates, shorter time to normal diet and length of stay^{6,7} without compromising oncologic safety as compared to open surgery.⁸ Several urinary diversions have been described, but only limited randomized clinical trials performed by few super-specialized tertiary referral centers have demonstrated the advantages offered by intracorporeal urinary diversion (ICUD). The potential advantages of a complete intracorporeal procedure are less intraoperative blood loss, decreased bowel manipulation and exposure, reduced insensible losses,

decreased morbidity from smaller incisions, reduced postoperative analgesic requirements, shorter hospital stay and earlier return to normal activities.⁹

In this paper we describe our approach for intracorporeal neobladder formation performed from December 2003.

Materials and methods

In this chapter, we describe our standardised approach to modified Studer intracorporeal neobladder formation performed from 2003 identifying potential hazard steps and identifying strategies to help avoid complications. Particularly attention has been placed in patient selection, preoperative preparation, Enhanced Recovery Protocol (ERP), operative set-up including patient positioning, and the equipment required

Patient selection, inclusion and exclusion criteria

The selection process includes preoperative investigation to ensure fitness for surgery as well as specific counselling about robotic technology. The exclusion criteria for RARC include: 1) bulky tumors with persisting signs of locally advanced/frozen pelvis cancer, extensive lymph node involvement, after neoadjuvant chemotherapy (cT4 disease); 2) history of extensive abdominal surgery; 3) the presence of contraindications to laparoscopy and steep Trendelenburg position (30°): severe cardiac and/or lung insufficiency; 4) relative contra-indications include avoiding bulky tumors (cT3-4) early in the learning curve, age >75 years and body mass index (BMI) >30.

In the absence of contraindications and following appropriate discussion, patients chose between an open procedure and RARC with totally intracorporeal orthotopic ileal neobladder or ileal conduit.

Preoperative preparation and enhanced recovery protocol

In order to reduce peri-operative stress response and to aid faster patient recovery we routinely apply an Enhanced Recovery Protocol (ERP).^{10–12} Our multidisciplinary team routinely suggests the patient preoperative smoking cessation, weight loss and physical activity. Medical comorbidities are addressed and cardiopulmonary testing is completed where indicated. Social issues are identified and discharge planning is agreed before admission. The ERP protocol advises no pre-operative mechanical bowel preparation, pre-medication includes omeprazole and metoclopramide with the avoidance of anxiolytics preoperatively. Post-operatively avoidance of the use of opiate based analgesia, early post-operative nasogastric and drainage tubes removal as well as early feeding and patient mobilization. All patients have a stoma site marked the day before surgery. One dose of broad spectrum intravenous antibiotics are administered at the start of the procedure.

Operative set-up

After induction of general anesthesia and naso-gastric tube and sterile urinary catheter insertion, patient is placed in lithotomy position with arms adducted and padded. The lower limb calves are wrapped with Flowtron pneumatic compression stockings and then placed and secured within stirrups where they can be abducted and slightly lowered on spreader bars. The table is placed in the 25–30° Trendelenburg position.

After the first 20 consecutive cases performed with the Standard da Vinci surgical platform (Intuitive Surgical, Sunnyvale, CA, USA), nowadays, both Si and Xi system are alternatively used. The technique has evolved with experience from 2003 and the technique described in this chapter has been used since 2008. A 0° lens is used.

Standard robotic instruments are: Maryland Bipolar Forceps, Large Needle Driver, Monopolar Curved Scissors, Cadiere forceps and bowel graspers.

Among other standard laparoscopic surgical equipment, essential additional instruments are required: LigaSure® (Covidien plc,

Dublin, Ireland), surgical endoscopic clip applicators, laparoscopic Endo-Catch bags and laparoscopic stapler with 60 mm and 45 mm cartridges for intestinal stapling.

Surgical technique

Trocar configuration

RARC is commonly performed via a 6-port laparoscopic approach. A 5-cm supraumbilical optical port position is placed with the Hasson technique; the other ports are placed in view of the camera. A pneumoperitoneum pressure of 18 mmHg during the port placement can be helpful in creating additional tension on the abdominal wall. Two robotic ports are placed symmetrically and level with the umbilicus on the left and right side, lateral to the rectus sheath. A third robotic instrument port is placed just above and medial to the left anterior superior iliac spine through a 15-mm port thereby enabling laparoscopic stapling by the assistant when the third robotic port is temporarily disconnected. Two assistant ports are placed on either side of the right robotic instrument port (Figure 7.2.3.1). The pneumoperitoneum can then be reduced to 10–12 mmHg.

Orthotopic neobladder, intracorporeal technique

Step 1. Development of peri-ureteral space, clipping and division of ureters. The ureters are identified and the peritoneum covering them is carefully opened. The ureters are dissected out towards the bladder, holding them by the peri-ureteric tissue and maintaining adequate peri-ureteral tissue. Avoid excessive dissection of the peri-ureters, as this causes increased risk of strictures. Close to the ureterovesical junction, they are divided between two Hem-o-Lok clips. The Hem-o-Lok clips on the ureter end are knotted at their corner with a suture to facilitate the handling of the ureter: a direct manipulation of the ureter with the robotic instruments during construction of the urinary diversion, should be avoided in order to prevent ureteric trauma and later strictures. The distal ureteric margin may be sent for frozen section.

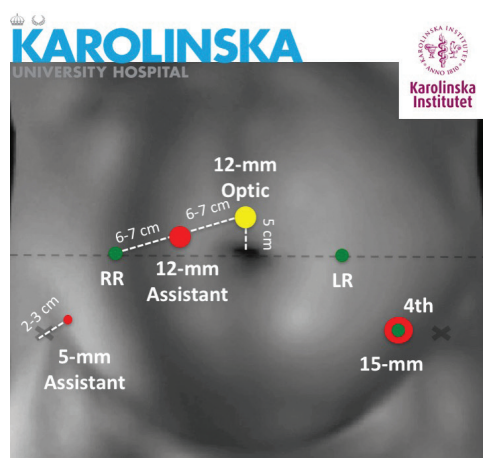


FIGURE 7.2.3.1 Ports configuration. Karolinska 6 port approach. Camera port 5 cm supraumbilically. Two 8-mm robotic ports are placed symmetrically and level with the umbilicus on the left and right side, lateral to the rectus sheath. The 3rd robotic port is placed through a 15-mm just above and medial to the left anterior superior iliac spine. Two assistant ports (12- and 5-mm) are placed on either side of the right robotic instrument port.

Step 2. Passing the left ureter to the right side under the mesosigmoid. After completion of RARC and ePLND, the presacral area under the mesosigmoid is already prepared, as the lymph nodes below the aortic bifurcation are removed at both sides.¹² The robotic Cadieere forceps are passed under the sigmoid from the right to the left side. The left ureter is grasped by the stay suture and brought to the right side. In this step careful attention should be paid to move the instrument in a horizontal direction in order to avoid damage to the vessels or nerves that lie posteriorly.

Step 3. Identifying and selection of terminal ileum. An ileal loop of 40cm is required to form the ileal neobladder, this harvested loop should be at least 20-25 from the ileo-caecal junction. A section of ileum is identified with a distance of at least 35-40 cm from the ileo-caecal junction is selected and brought down to the urethra. The ileum is sufficiently mobilized to reach down to the urethra without tension. A 20 Fr opening is made on the antimesenteric side of ileum, using cold robotic scissors (Figure 7.2.3.2A).

In case of a short mesentery or fatty-mesentery, the ileum can be difficult to mobilise

sufficiently to come down into the pelvis and therefore undermining the ability to complete a neobladder. To obtain precious millimeters to get the ileum down to the urethra different solutions can be attempted:

- complete dissection of all adhesions;
- detachment of the cecum and the first part of the ascending colon;
- superficial incision of the peritoneal layer on the mesentery in a line parallel with the ileum, making sure that the incision is not damaging the mesenteric vessels below;
- reducing Trendelenburg;
- to assist the manipulation and positioning of the ileum, two vessel loops are passed around the intestine through the mesentery either side of the section of ileum loop to be anastomosed to the urethra.

Step 4. Posterior reconstruction. Our evolved technique now includes a modified posterior Rocco's repair¹³ with a barbed suture with 2 needles (3-0 Quill SRS; Angiotech, Reading, PA, USA) suturing the rhabdosphincter and the median fibrous raphe to the remaining Denonvillier's fascia in a running fashion. The resulting reconstructed plane is then fixed to the posterior aspect of the ileum at the level of opening for the ileal-urethral anastomosis (neobladder neck) approximately 8 mm dorsocephalad. Putting traction on this suture, the opening for the neobladder neck descends towards the urethral stump (Figure 7.2.3.2B). The anastomosis between the neobladder and urethra can then be then made without tension, and this manoeuvre also ensures the neobladder will be placed correctly in the small pelvis during the whole procedure.

Step 5. Urethro-neovesical anastomosis. The anastomosis between ileum and urethra is then performed according to the Van Velthoven technique, with two 16 cm 2-0 Quill suture, allowing for 10-12 suture passes (Figure 7.2.3.2C).¹⁴ The running suture is commenced by placing both needles from outside to in through the new-"bladder neck", one needle at the 5:30- and the other at the 6:30 o'clock position, so that the "middle" sits at the 6-o'clock position on the posterior neobladder neck. The urethral "bites" are then made from inside to out, at

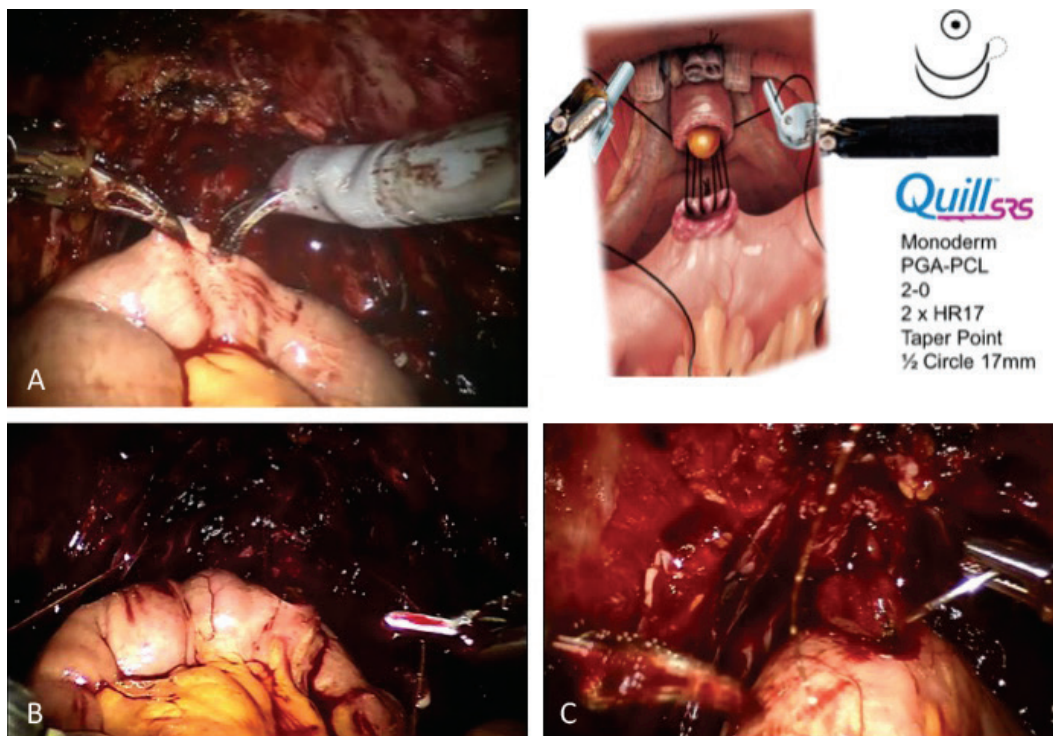


FIGURE 7.2.3.2 Urethro-neovesical anastomosis: A) new urethra opening A 20 Fr opening is made on the antimesenteric side of ileum, using cold robotic scissors; B) modified posterior Rocco's repair; C) urethro-neovesical anastomosis.

the corresponding sites. At this point, perineal pressure, if needed, can be applied. After two such placement on each side, which covers the completed posterior aspect of anastomosis, the neobladder neck is brought down together with the major portion of the ileal loop by tightening both sutures. In order to avoid urethral tearing, we suggest to gently lift upward the suture only after passing through the urethra and by alternate the left and the right needle in a “marionette technique” to get the ileum to “snug down”. At 12-o'clock position, both suture arms are tied to each other over the urethra. The catheter balloon is then temporary inflated to 5 mL.

Step 6. Section of ileum segment and commencing the orthotopic reservoir. The orthotopic neobladder is fashioned from a 50 cm segment of terminal ileum. After the urethral-ileum anastomosis, an ileal inverse-U-shaped loop is obtained (Figure 7.2.3.3A, 3B). The Endo-GIA stapler is inserted by the bed side assistant through the left hybrid 15-mm trocar and a charge of 60 mm fired twice over the ileum (Figure 7.2.3.3C), to obtain select

an ileal segment going from 20-25 cm from the ileocaecal valve and 15 cm from the urethral-enteric anastomosis and 40 cm from the urethral-enteric anastomosis, to obtain the afferent reservoir loop. The selected point included not more than 3-4 cm of its mesentery.

Step 7. Restoring continuity of the ileum (side-to-side entero-enteric anastomosis). A side-to-side ileum anastomosis is performed by opening a 1-cm hole at the antimesenteric bowel border just next to the staple line. The continuity of the bowel is restored by inserting through these holes, the jaws of the stapler and fired twice with 60 mm firing (Figure 7.2.3.3D). The transverse opening is then closed by an additional 60 mm firing of the stapler.

Step 8. Detubularisation of ileum. The intestinal loop is then detubularised with robotic scissors along the anti-mesenteric border apart from the last 12-14 cm of the distal 40 cm of the isolated ileal segment (Figure

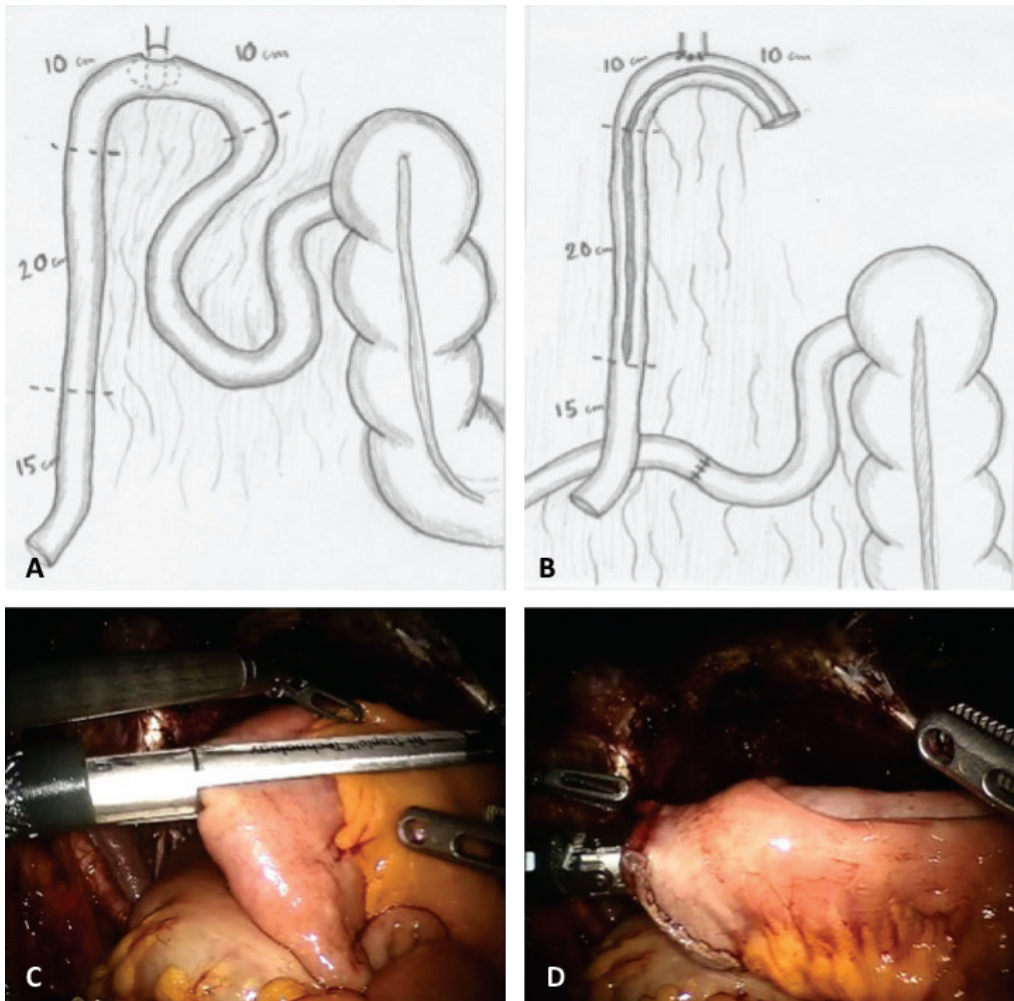


FIGURE 7.2.3.3 Forming the modified Studer neobladder: the orthotopic neobladder is fashioned from a 45-50 cm segment of terminal ileum: A) the ileal inverse-U-shaped loop is obtained after urethro-enteric anastomosis and intestine stapling; B) endoscopic view of Endo GIA stapler and ileum. The selected point include not more than 3-4 cm of its mesentery; C) restoring continuity of the ileum (side-to-side entero-enteric anastomosis).

7.2.3.4A). Careful attention has to be paid at level of the anastomosis, where the incision can be performed closer to the mesenteric border, by keeping a safe distance from the anastomosis. The left ileum loop will be preserved, as the proximal iso-peristaltic afferent limb for the ureteral anastomosis.

Step 9. Construction of the posterior wall of the reservoir. The posterior part of the reservoir is closed using a multiple running self-anchoring suture (V-Loc® closure device, Covidien V-Loc 180 3-0, Mansfield, MA, USA) in a seromuscular fashion. After applying traction

sutures every 5-7 cm on the posterior aspect (Figure 7.2.3.4B), the running suturing start from the proximal aspect of the detubularised bowel (Figure 7.2.3.4C, 4D).

Step 10. Folding and constructing the anterior wall of the reservoir. To achieve a spherical reservoir consisting of four cross-folded ileal segments, similar to the Studer neobladder,¹⁰ the right upper bottom of the U is folded over approximating diagonally to the left limb of reservoir loop, at 7-10 cm from the urethral-enteric anastomosis (Figure 7.2.3.5A,5B). The distal half of the anterior part of the reservoir is

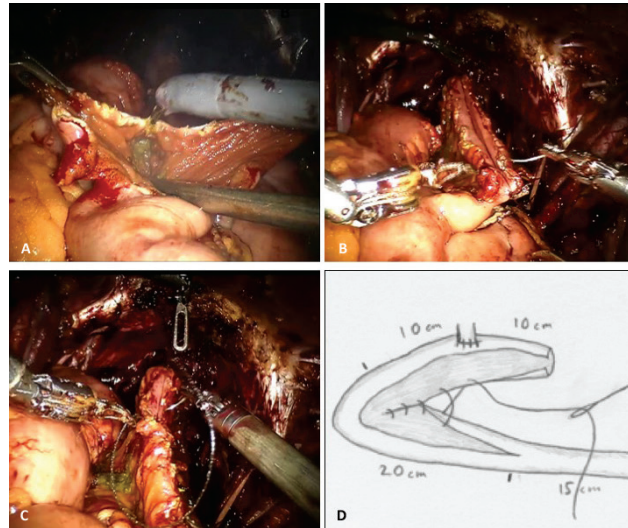


FIGURE 7.2.3.4 Construction of the posterior wall of the reservoir: A) detubularisation of ileum; B) role of traction sutures every 5-7 cm on the posterior aspect; C, D) multiple running self-anchoring suture (V-Loc® closure device).

then sutured (Figure 7.2.3.5C), while the proximal half is temporary left open, to let ureteric stents passing through the abdominal wall.

Step 11. The uretero-enteric anastomosis. At this point, the staple line of the afferent reservoir loop is excised and a Wallace technique is adopted for the uretero-enteric anastomosis: while the fourth arm holding still the ties attached to Hem-o-lok clips, the ureters are aligned. Following ureters incision and spatulation for 2 cm (Figure 7.2.3.6A), the posterior walls of ureters are sutured side-to-side with a 15-cm running 5-0 Biosyn suture (Synature, Covidien)(Figure 7.2.3.6B). Bilateral single-J, 40-cm ureteric stents are introduced with the Seldinger technique through two separate 4-mm suprapubic incisions (Figure 7.2.3.6C). Using the Cadere forceps, the stents are pulled through the afferent limb and pushed up into the ureters on each side. The ureters are then sutured to the afferent limb of the Studer pouch, using two-times 16 cm 3-0 Quill suture. After the entero-ureteric anastomoses are completed the stents are sutured and fixed to the skin

Step 12. Closure of the neobladder. The remaining part of the neobladder is then closed with a running 3-0 V-Loc suture. The balloon of the final indwelling catheter is filled

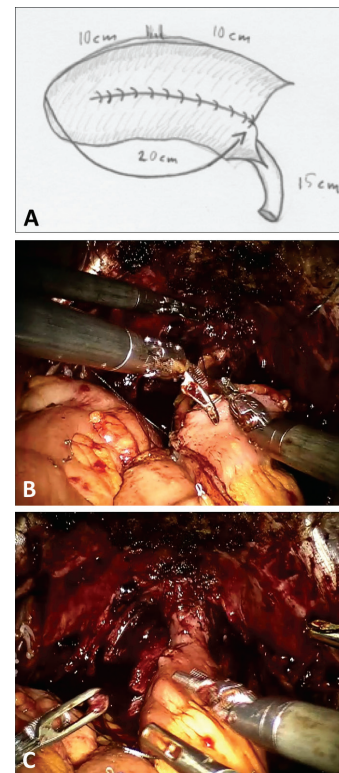


FIGURE 7.2.3.5 Folding and constructing the anterior wall of the reservoir: A, B) folding: the right upper bottom of the U is folded over approximating diagonally to the left limb of reservoir loop, at 7-10 cm from the urethral-enteric anastomosis; C) suturing the distal half of the anterior part of the reservoir.

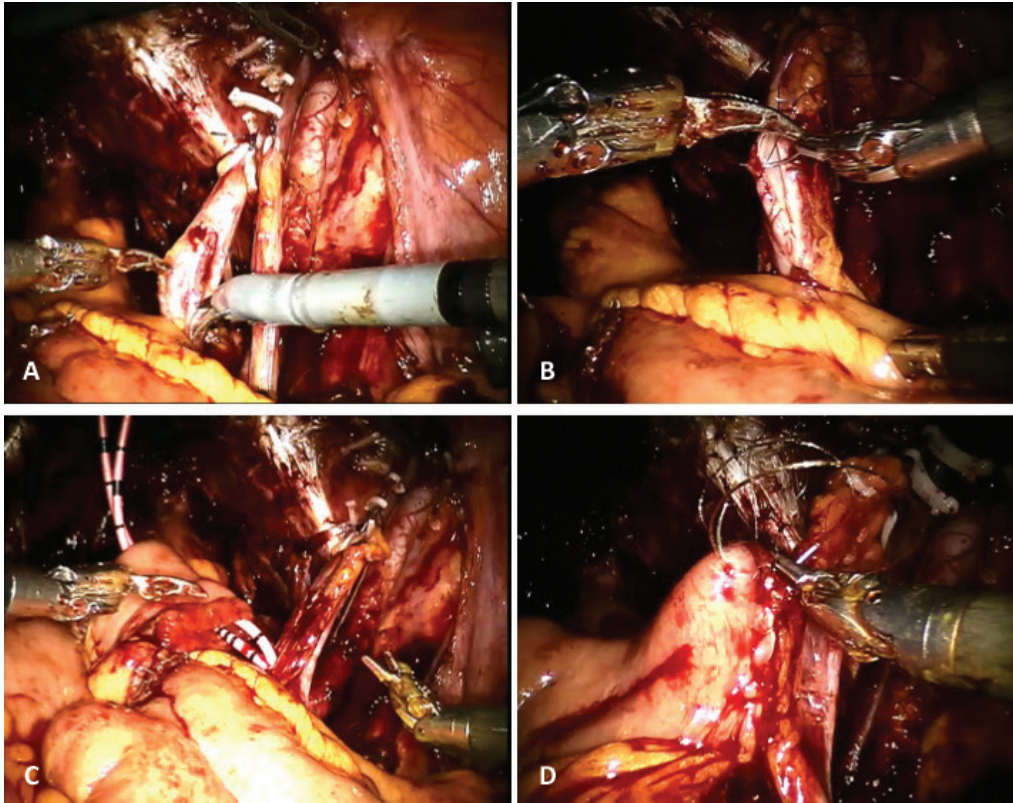


FIGURE 7.2.3.6 The uretero-enteric anastomosis (Wallace I): A) ureters incision and spatulation for 2 cm; B) posterior walls of ureters are sutured side-to-side with a 15-cm running 5-0; C) bilateral single-J, 40-cm ureteric stents; D) the ureters are then sutured to the afferent limb of the Studer pouch, using two-times 16 cm 2-0 Quill suture.

with 10 mL. The neobladder is then filled with 50 mL of saline to check for leakage. When necessary extra suturing is fundamental to secure a watertight reservoir. A passive drain is then introduced and placed in the small pelvis.

Postoperative care

In an ERP schedule, nasogastric tube is early removed in recovery room. Drain fluid is routinely sent for creatinine analysis on post-operative day (POD) 1 and the drain can be removed from POD 1 if fluid indicates serum creatinine levels. Both compression stockings and low molecular weight heparin is routinely administered for 3-4 weeks postoperatively. Single J's will be removed POD 10-12.

Conclusions

A totally intracorporeal RARC with urinary diversion is gaining popularity as a realistic

alternative to open surgery. RARC with intracorporeal neobladder performed in experienced robotic centers have reported functional and complication rates comparable to open series with the potential advantages over open approach, which include reduced blood loss and length of stay. However, totally intracorporeal RARC represents a complex multi-step procedure and we highlight the importance of adequate planning, proper mentoring while commencing this procedure, initiation of an ERP and establishment of a dedicated RARC team with continual auditing of results.^{9,10}

References

1. Stenzl A, Cowan NC, De Santis M, *et al.* Treatment of muscle-invasive and metastatic bladder cancer: update of the EAU Guidelines. *Eur Urol* 2011;59:1009-1.
2. Collins JW, Adding C, Hosseini A, *et al.* Introducing an enhanced recovery programme to an established totally intracorporeal

- robot-assisted radical cystectomy service. *Scand J Urol* 2016;50:39-46.
3. Witjes JA, Comp  rat E, Cowan NC, *et al.* Guidelines on Muscle-invasive and Metastatic Bladder Cancer. [Internet] http://uroweb.org/wp-content/uploads/07-Muscle-Invasive-BC_LR.pdf.
4. Collins JW, Tyrirtzis S, Nyberg T, *et al.* Robot-assisted radical cystectomy: Description of an evolved approach to radical cystectomy. *Eur Urol* 2013;64:654-63.
5. Yu D, Dural C, Morrow MM, *et al.* Intraoperative workload in robotic surgery assessed by wearable motion tracking sensors and questionnaires. *Surg Endosc* 2017;31:877-86.
6. Tang K, Xia D, Li H, *et al.* Robotic vs. open radical cystectomy in bladder cancer: A systematic review and meta-analysis. *Eur J Surg Oncol* 2014;40:1399-411.
7. Li K, Lin T, Fan X, *et al.* Systematic review and meta-analysis of comparative studies reporting early outcomes after robot-assisted radical cystectomy versus open radical cystectomy. *Cancer Treat Rev* 2013;39:551-60.
8. Snow-Lisy DC, Campbell SC, Gill IS, *et al.* Robotic and laparoscopic radical cystectomy for bladder cancer: long-term oncologic outcomes. *Eur Urol* 2014;65:193-200.
9. Collins JW, Wiklund P, Goh AC, *et al.* Total intracorporeal robotic cystectomy-are we there yet? *Curr Opin Urol* 2013;23:135-40.
10. Collins JW, Patel H, Adding C, *et al.* Enhanced Recovery After Robot-assisted Radical Cystectomy: EAU Robotic Urology Section Scientific Working Group Consensus View. *Eur Urol* 2016;70:649-60.
11. Cerantola Y, Valerio M, Persson B, *et al.* Guidelines for perioperative care after radical cystectomy for bladder cancer: Enhanced Recovery After Surgery (ERAS[®]) society recommendations. *Clin Nutr* 2013;32:879-87.
12. Pini G, Matin SE, Suardi N, *et al.* Robot assisted lymphadenectomy in urology: pelvic, retroperitoneal and inguinal. *Minerva Urol Nefrol* 2017;69:38-55.
13. Rocco F, Rocco B. Anatomical reconstruction of the rhabdosphincter after radical prostatectomy. *BJU Int* 2009;104:274-81.
14. Van Velthoven RF, Ahlering TE, Peltier A, *et al.* Technique for laparoscopic running urethrovesical anastomosis: the single knot method. *Urology* 2003;61:699-702.
15. Wiklund NP, Poulakis V. Robotic neobladder. *BJU Int* 2011;107:1514-37.